

# Anatomic Variations of the Right Hepatic Duct: Results and Surgical Implications From a Cadaveric Study

Akinchan Kafle,<sup>1</sup> Bidur Adhikari,<sup>2</sup> Rajani Shrestha,<sup>2</sup> Nirju Ranjit<sup>2</sup>

<sup>1</sup>Department of Anatomy, Patan Academy of Health Sciences, Patan, Lalitpur, Nepal, <sup>2</sup>Department of Anatomy, Maharajgunj Medical Campus, Institute of Medicine, Tribhuvan University, Maharajgunj, Kathmandu, Nepal.

## ABSTRACT

**Background:** Right hepatic duct, formed by the confluence of the anterior and posterior right sectorial ducts, joins left hepatic duct to form common hepatic duct. This fashion of confluence does not prevail in all cases. The sectorial ducts can aberrantly meet left duct and rest of the ducts from the left lobe of liver. Presence of such variation imposes clinical importance during peri-hilar, split liver transplant surgery or cholecystectomy. Nepalese population has not been explored before disregarding clinical necessity as MRI or cholangiography.

**Methods:** Descriptive cross sectional study was conducted in 107 cases dissecting the main portal fissure separating hemi liver and extrahepatic biliary confluences. Methylene blue dye was injected and bile duct wall was cut open to the study pattern of the confluence. Data analysis was done with Statistical Package for Social Sciences (SPSS) version 17.

**Results:** Normal variant of confluence was found in 72% cases, aberrant right posterior sectorial duct joins left hepatic duct in 9.3% and aberrant right anterior duct or low insertion of the right posterior sectorial duct was found in 1.9%. 9.3% of cases there is no true right hepatic duct often described as triple confluence. 0.9% cases showed no particular pattern of confluence where common hepatic duct is formed by multiple confluence. Quadrate lobe was found to be draining into right anterior sectorial duct in a single case.

**Conclusions:** Right hepatic duct confluence pattern is variable and all the evidence occurs at the main portal fissure. Right sectorial duct may join the left duct avoiding normal confluence pattern. Right posterior sectorial duct may be inserted low in the common bile duct.

**Keywords:** Duct; hepatic; sectorial; variation.

## INTRODUCTION

Couinaud divided liver into eight functional segments.<sup>1,2</sup> Caudate lobe (segment I) lies posterior to Quadrate lobe (segment IV). Left lateral sector, posterolateral to left portal fissure, forms segment II. Portal sector, between umbilical and left portal fissure, comprises segment III. Segment V (inferior) and segment VIII (superior), between right and main portal fissure, comprise right anterior segment. This portal sector drains via right anterior sectorial duct (RASD). Segment VI (inferior) and segment VII (superior), posterior to right portal fissure, forms right posterior segment (right lateral portal sector), which drains through right posterior segmental duct (RPSD). Union of these two ducts forms right hepatic duct (RHD). RHD joins left hepatic duct (LHD) at the main portal fissure forming common hepatic duct (CHD).<sup>3,4</sup>

Variation of RHD in this population are not studied. In this study RHD, LHD and their confluence was dissected and explored.

## METHODS

This was a descriptive cross sectional study conducted in the Department of Forensics, Institute of Medicine, Maharajgunj Medical Campus. Ethical approval was obtained from Institution Review Board, Institute of Medicine, Tribhuvan University. Informed consent was obtained from the family members prior to use of livers. The study was conducted from 1<sup>st</sup> October 2013 to 30<sup>th</sup> March 2014. One third cases were taken available at forensic department during the study period. The cases amount to 131 cases. 24 cases were excluded. 6 cases of Cirrhosis of liver, 6 foreign national, 3 mutilated bodies,

**Correspondence:** Akinchan Kafle, Department of Anatomy, Patan Academy of Health Sciences, Patan, Lalitpur, Nepal. Email: [akiatirupa@gmail.com](mailto:akiatirupa@gmail.com), [akinchankafle@pahs.edu.np](mailto:akinchankafle@pahs.edu.np).

4 liver injury (fall injury), 3 cases of putrefaction, 3 cases were children below 10 years (due to difficulty of dissection).

107cases were dissected at main portal fissure. After identification of cystic duct and common hepatic duct, cystic duct variations associated with the right hepatic duct was explored. Methylene blue dye was injected into the common hepatic duct and clamped. Wall of the duct was cut open. This guided to the openings of the branches to the particular ducts. Thus the confluence pattern of RHD and its variations were noted.

The exposure of the right hepatic duct was achieved via separating hemi liver through main portal fissure. Division of between the segments V and VII was carried out in order to further expose confluence of the right hepatic duct. The observed variation were divided into different categories such as normal variant (RASD joins RPSD to form RHD and forms CHD joining LHD) , absence of right hepatic duct, low insertion of the RPSD, RPSD draining into LHD, multiple ducts forming CHD and RPSD draining into cystic duct.<sup>4</sup>

Data analysis was done with Statistical Package for Social Sciences (SPSS) version 17. A value for probability less than 0.5 (p<0.05) at 95% confidence interval was considered statistically significant.

**RESULTS**

Seventy two cases dissected were male and 35 were female. The chances of appearance of variations was not significantly different between these two groups within 95% confidence interval level (p= 0.316) as shown in the table 1.

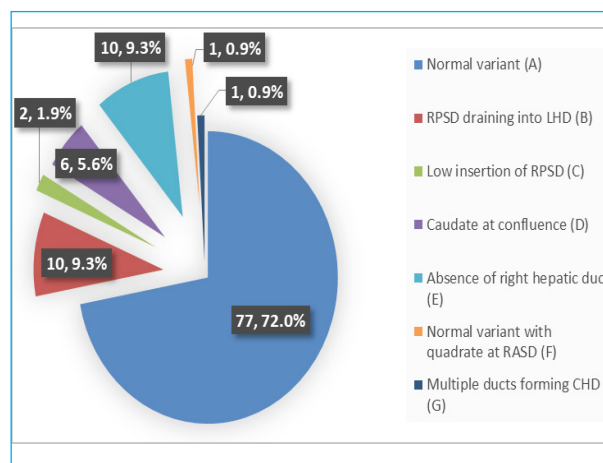
**Table 1. Cross tabulation between sex and variation observed with Chi-Square test.**

Sex of Cadavers	Category of Variation		Total	p value
	Normal	Variation		
Male	54	18	72	0.316
Female	23	12	35	
Total	77	30	107	

**Table 2. Crosstabulation between ethnicity and variation in biliary tree with chi-square test.**

Cadavers	Category of Variation				Total	p value
	Chhetri	Brahmin	Newar	Others		
Normal	16	21	9	31	77	0.010
Variants	3	7	12	8	30	
Total	19	28	21	39	107	

The variables shown in figure 2 are the patterns of confluence of right hepatic duct.



**Figure 1. Frequency distribution of the variations found in the population under study.**

The most abundant variant was normal variant where usually RASD joins RPSD and forms the CHD joining LHD as shown in figure 2A. It was seen in 72% of the population under study. 9.3% of the population had aberrant RPSD joining LHD (fig. 2B) crossing the main portal fissure. 1.9% of population had aberrant RASD joining the LHD described as low insertion of RPSD (fig. 2C) by Blumgart. In this study the drainage of Caudate lobe was found at the confluence in 6% of the population under study as shown in fig. 2D. CHD confluence was made by all three sectorial ducts in 10% of population understudy, there was no true RHD (fig. 2E) . There was a single case where normal variant with the quadrate lobe draining at the RASD (fig. 2F). Only one case presented with abnormal confluence where RHD was absent and the confluence was made via multiple biliary drainage shown in fig. 2G.

The most abundant cases were from Bramhin, Newar and Chhetri ethnic groups. Cross tabulation between variations of biliary tree and these three ethnic groups is shown in table 2.




Figure 2. (A-G): Photos and pictorial diagrams of all the variations observed. I-VIII denote Couinaud's Segments, ra=RASD, rp=RPSD, lh= LHD.

## DISCUSSION

The confluence of the sectorial duct as a normal variant was described in 57% by Couinaud.<sup>1</sup> Mariolis-Sapsakos<sup>5</sup> described such configuration in 65% and Sharma-Saraswat in 63%.<sup>6</sup> RPSD ectopic draining into LHD was found more common up to 15% by Mariolis-Spsakos.<sup>5</sup> Saraswat-Sharma<sup>6</sup> recorded up to 18.2%. The variation described by Blumgart<sup>4</sup> and Couinauds<sup>1</sup> as low inserting posterior sectorial duct type occurred in 4% population. Such variation is defined as a separate entity from the ectopic RASD by Sharma-Saraswat,<sup>6</sup> 7.1%, 6% in Choi-Kim.<sup>7</sup> Caudate at the confluence was not kept as the different entity in any of the studies. Couinaud<sup>1</sup> and Blumgart<sup>4</sup> described such entity as part of multiple ducts forming confluence. These variants were found in 3% of the cases described by Couinaud.<sup>1</sup> Choi<sup>7</sup> described such variation as complex variation in 1%. Aberrant quadrate lobe drainage into the right anterior sectorial duct was not described in any of the previous studies.

The formation of a normal biliary confluence as described above is reported in only 57%<sup>1</sup> to 72% of cases. 20% of

the cases right sectorial duct might join main hepatic duct directly. 16 % RASD and 4% RPSD may approach the main bile duct in this fashion. Furthermore in 6% right sectorial duct may join the left hepatic duct (5% RPSD, 1% RASD). In 3 % there is multiple ducts forming confluence and in 2% the RPSD may join neck of gall bladder of cystic duct.<sup>4</sup>

The right lobe of liver is used for an adult and left lobe is usually used for a pediatric recipient for split liver transplants.<sup>8</sup> Right sided extended liver transplant is preferred to left lobe in case of adult because the metabolic need is compromised for the adult in case of the left sided liver transplant.<sup>9</sup> Biliary complications are the most common and feared complications in living donors. There are more frequent and severe complications for right and extended right lobe donation.<sup>10</sup>

In approximately 20%<sup>1</sup> of cases there is no true right hepatic duct. In these cases either the RASD or RPSD joins the left hepatic duct. It is not of consequence in a right hepatectomy if these ducts are divided separately during the transaction of the liver. However, there is threat in left hepatectomy because when coming through the liver just to the left of the mid-plane it is possible to divide the aberrant right duct leaving one-half of the remnant right liver without biliary drainage into the intestine.<sup>11</sup>

Although the current study shows significant association of variations with ethnicity, further studies with larger sample need to be done to consolidate this result.

## CONCLUSIONS

The right hepatic bile duct formation can vary during the confluence. RPSD and RASD can both cross the main portal fissure to form the CHD or both may directly join CHD without crossing the main portal fissure.

Typical confluence of the sectorial ducts, RASD joining RPSD and later at the main portal fissure with LHD is the most common pattern. However, it is common that the sectorial ducts on the right side joins the sectorial ducts on the left side in atypical manner.

## REFERENCES

1. Couinaud C. Le foie. Etudes anatomiques et chirurgicales. 1957.
2. Gray H. Gall bladder and Biliary tree. In Gray H, Standring S. Gray's anatomy: The anatomical basis of clinical practice. London: Churchill Livingstone; 2008. p. 1177-82. [\[PubMed\]](#)

3. Gazelle GS, Lee MJ, Mueller PR. Cholangiographic segmental anatomy of the liver. *Radiographics*. 1994;14(5):1005-13. [\[DOI\]](#)
4. Blumgart LH, editor. *Surgery of the liver and biliary tract*. New York: Churchill Livingstone; 1998. p. 16-17.
5. Mariolis-Sapsakos T, Kalles V, Papatheodorou K, Goutas N, Papapanagiotou I, Flessas I, et al. Anatomic variations of the right hepatic duct: results and surgical implications from a cadaveric study. *Anat Res Int*. 2012;2012:838179. [\[DOI\]](#)
6. Sharma V, Saraswat VA, Bajjal SS, Choudhuri G. Anatomic variations in intrahepatic bile ducts in a north Indian population. *J Gastroenterol Hepatol*. 2008;23(7pt2):e58-62. [\[DOI\]](#)
7. Choi JW, Kim TK, Kim KW, Kim AY, Kim PN, Ha HK, Lee MG. Anatomic variation in intrahepatic bile ducts: an analysis of intraoperative cholangiograms in 300 consecutive donors for living donor liver transplantation. *Korean J Radiol*. 2003;4(2):85-90. [\[DOI\]](#)
8. Marcos A, Fisher RA, Ham JM, Shiffman ML, Sanyal AJ, Luketic VA, et al. Right lobe living donor liver transplantation. *Transplantation*. 1998;68:798-803. [\[DOI\]](#)
9. Lo CM, Fan ST, Liu CL, Wei WI, Lo RJ, Lai CL, Chan JK, Ng IO, Fung A, Wong J. Adult-to- adult living donor liver transplantation using extended right lobe grafts. *Ann Surg*. 1997;226(3):261. [\[DOI\]](#)
10. Iida T, Ogura Y, Oike F, Hatano E, Kaido T, Egawa H, Takada Y, Uemoto S. Surgery- related morbidity in living donors for liver transplantation. *Transplantation*. 2010 May 27;89(10):1276-82. [\[DOI\]](#)
11. Garden OJ. *Hepatobiliary and Pancreatic Surgery: Companion to Specialist Surgical Practice*. Elsevier Health Sciences; 2005. [\[Full Text Link\]](#)