

Diagnostic Accuracy of Fine Needle Aspiration Cytology in Thyroid Swellings

Bista M,¹ KC Toran,¹ Regmi D,¹ Maharjan M,¹ Kafle P,¹ Shrestha S¹

¹Department of Ear, Nose Throat Head and Neck Surgery, Kathmandu Medical College, Sinamangal, Kathmandu, Nepal.

ABSTRACT

Background: Proper management of the disease depends upon accurate diagnosis. Fine Needle Aspiration Cytology has become the investigation of choice because of its high accuracy, simplicity, minimal-invasiveness, quick result and reliability.

Methods: All the patients with thyroid disease, irrespective of age and gender, who underwent thyroid were studied. These patients had their fine needle aspiration Cytology was done in our centre. Detailed history, physical examination, routine investigations, radiological investigations (including CT scans when needed), hormonal assay, (T3, T4, TSH), ultrasound of neck and FNAC were done. Pre-operative fine needle aspiration results were compared with histopathology results of operated specimen and then analyzed statistically to assess the sensitivity, specificity and accuracy of the result.

Results: There were total of 51 patients. Age ranges from 21 to 62 years. The study duration was from May 2006 to February 2011. Out of 51 patients, 82.35% (n=42) were females and 17.64% (n=9) were males. In 43 patients, FNAC showed benign lesions, of which 40 were true negative (TN) and three false negative (FN), which on histopathology reported malignancy. Remaining eight cases were diagnosed as malignancy on histopathology of which seven cases were true positive (TP), one case of false positive (FP) was detected in our study. Over all Sensitivity was 70% and specificity was 97.5% and accuracy of FNAC was 92.1%.

Conclusions: FNAC should be performed in all cases of thyroid nodules because of its high sensitivity and specificity to differentiate benign from malignant lesions and counsel the patient as well as plan surgery accordingly. Expenditure, time and the hassle of revision surgery is minimized by the pre operative FNAC report.

Keywords: fine needle aspiration cytology, histopathology, sensitivity, specificity, thyroid swellings.

INTRODUCTION

Fine Needle Aspiration Cytology (FNAC) can provide exact morphological diagnosis in a large variety of thyroid lesions. Thus it has become an integral part in the management of thyroid swellings since half a century but has gained worldwide acceptance during the last two decades. Soderstorm and Franzen used FNAC for the first time in 1950's and 1960's.¹ FNAC is

cost-effective, simple, less time consuming, minimal-invasive and can be performed in outpatient basis. Thus cytology has become the first choice in assessment of thyroid disease. Other modalities of investigations like radio isotope scan, Floro-d-glucose positron emission tomography (FDG- PET Scan), ultrasonography, hormonal assay, computed tomography, radiography can be used,

Correspondence: Dr. Meera Bista, Department of Ear, Nose Throat- Head and Neck Surgery, Kathmandu Medical College Teaching Hospital, Baburam Sadak, Sinamangal, Kathmandu, Nepal. Email: meerabista@hotmail.com, Phone: 9841256711.

but the information provided is only functional status of the gland. Thus this study is designed to find out the importance of FNAC as a definitive diagnostic test in our setting.

METHODS

A cross sectional study was conducted from May 2006 to February 2011 in Department of ENT-HN Surgery in Kathmandu medical College Teaching Hospital. The ethical approval and patient consent was taken. The study included the patients presenting with thyroid swelling who were randomly selected irrespective of age and gender. Total of fifty one patients were included. Patients with advanced fixed tumours, not fit for surgery and patients who had done FNAC outside Kathmandu Medical College were excluded from the study. All routine investigations like complete blood tests, hormonal assay (T₃, T₄, TSH), radiological examination, Computed tomography, ultrasonography, indirect laryngoscopy and FNAC were done. USG guidance in aspiration was taken in nodules less than one cm, multinodular goitres, if the nodule was seen in the posterior part of thyroid swelling and in cases of high suspicion of malignancy like micro calcifications, hypoechoic or hyperechoic areas, cystic areas in thyroid swellings.² The post operative specimen after thyroid surgery was sent for histopathological examination. Histopathology and FNAC results were compared and analyzed for accuracy of FNAC. Data was analyzed by SPSS 10.0 and sensitivity and specificity of FNAC were calculated.

RESULTS

The study involved 51 patients (21 to 62 years of age), mean age was 41.5years. Among them 17.64% (n=9) were male and 82.35% (n=42) were females. According to this study the most common age of presentation was in the 3rd and 4th decades (Figure 1). FNAC revealed 15.68% (n=8) malignant and 84.31% (n=43) cases of benign lesions. Histopathology confirmed 19.6% (n=10) cases of malignancy and 80.39% (n=41) cases of benign lesions (Figure 2). Among these ten cases, eight had papillary carcinoma, one had medullary carcinoma and one had anaplastic carcinoma. Hemithyroidectomy was performed in 35 patients, near total thyroidectomy was done in four cases, total thyroidectomy was done in 11 cases, among them three had level VI (central compartment) clearance and total thyroidectomy with modified neck dissection was done in one case. All the patients with total thyroidectomies were kept in thyroid replacement therapy. Patients who had undergone total thyroidectomy for malignancy were sent abroad

for radio iodine ablation therapy and were kept under regular observation. One patient with anaplastic carcinoma developed superior venacaval syndrome and succumbed in three months time. The accuracy of FNAC was assessed by using SPSS 10.0. Over all sensitivity and specificity were calculated as 70% and 97.5% respectively with accuracy of 92.1% (Table 1, 2).

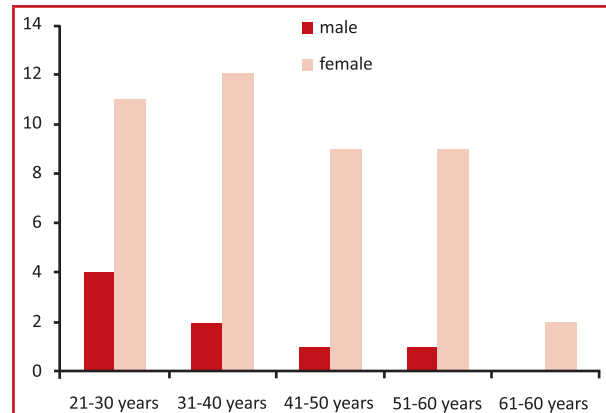

Figure 1. Age and sex distribution of thyroid swellings

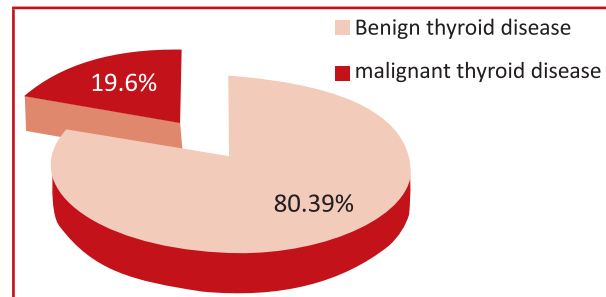


Figure 2. Distribution of benign and malignant

Table 1. Statistical analysis of thyroid gland biopsy results.

Test (FNAC)	Disease Positive (TN, FN)	Disease Negative (FN, TN)
Positive	7	1 FP
Negative	3	40 TN

TP=True Positive , FP=False Positive, TN=True Negative, FN=False Negative

Table 2. Sensitivity, specificity and accuracy of the result.

Sensitivity	Specificity	Accuracy
TP/TP+FN ×100 (7/10×100=70%)	TN/TN+FP×100 (40/41×100=97.5%)	TP+TN/Total No = (47/51×100=92.1%)

TP=True Positive , FP=False Positive, TN=True Negative, FN=False Negative

DISCUSSION

Fine Needle Aspiration Cytology is a well established technique for pre operative investigation of thyroid swellings. This technique is the single most sensitive, specific and cost-effective method in the investigation of thyroid nodules.³ In this study the age range was from 21 to 62 years and the mean age was 41.5 years. Most common age for thyroid disease was fourth decade of life. Female and male ratio is 4.6:1 (Figure 1). In the study it was seen that thyroid disease is more common in females than men. It is stated that females have 4 times more chance of having thyroid disease.⁴ This is similar with other studies done by S. U.Z. Bhatti et al. and M. Saddique et al which showed male and female ratio of 4:1 and 6.5:1 respectively.^{5,6} Goitre is seen in general population with a frequency varying between 4-10%.⁶ The prevalence of thyroid cancer is quite rare ranging in between 3-11% of thyroid pathologies and the common type is papillary carcinoma.^{8,9} In our study malignancy in thyroid disease is seen to be 19.6% (n=10) and the most common type is again papillary carcinoma which is 80.5% (n=8) of all malignancies (Figure 2). In this study sensitivity of FNAC is 70% and specificity is 97.5% (table 2). It coincides with the study done by M. Saddique et al. which shows sensitivity of 75% and specificity of 95.8%.⁶ In a review of FNAC of thyroid nodules, it was reported to have sensitivity range from 65-98% and specificity range 72 -100%.⁸ In a similar study by G -Matos L et al. sensitivity is 73.3% and specificity is 100 %, which shows FNAC is more specific than sensitive.⁹ The accuracy of the test in this study is 92.1% (Table 2), which is comparable to the study of M. Saddique et al. is 96.6%.⁶ and in a study by S. Kumar et al. where it is 97.7%.⁷ The fallacies of FNAC can be minimized by using ultrasound guidance as we did in required cases. Like wise serum calcitonin measurement can detect C-cell hyperplasia and micromedullary carcinoma which can be treated at an early stage if detected on time.¹⁰ Other group where FNAC is mandatory and has higher likelihood of malignancy are patients with family history of papillary carcinoma of thyroid or has history of external beam or ionising radiation exposure in childhood.² This category also includes prior history of thyroidectomy with discovery of thyroid cancer or FDG-PET positive thyroid nodules.¹¹

CONCLUSIONS

As thyroid is easily accessible, its FNAC is a simple and minimally invasive, safe and out patient based procedure. It shows high sensitivity and high specificity. The accuracy of the test allows the surgeon to do a more

definitive procedure in the first surgery itself rather than revision surgery in the second sitting. Occasionally false negative results occur due to faulty sampling technique but modern techniques like ultra sound guided aspiration, FDG-PET scan and serum calcitonin measurement has the ability to minimize these fallacies. Thus the role of FNAC of thyroid swellings as the most important, reliable diagnostic test cannot be overemphasized.

REFERENCES.

- Orell S, Sterrett G, Walters M, Whitaker D. Introduction: historical perspective: Manual and atlas of fine needle aspiration cytology. New York; Chirchull Livingstone: 1986. p. 1-5.
- Cooper DS, Dotherty GM, Haugen BR, Kloos RT, Lee SL, Mandel SJ. Revised American Thyroid Association Management Guidelines for patients with thyroid nodules and differentiated thyroid cancer. *Thyroid*. 2009;19(11):1167-214.
- Van Herle A J, Rich P, Ljung B M E. The thyroid nodule. *Ann Intern Med*. 1982;96:221-32.
- Silverman JF, West RE, Larkin EW, Park HM, Finley JL, Swanson MS. The role of FNAC in rapid diagnosis and management of thyroid neoplasm. *Cancer*. 1986 Mar 15;57(6):1164-70.
- Sher Uz Zamn Bhatt, Muhammad Saif Ul Malook Ali Zuqarnain. Diagnostic accuracy of fine needle aspiration cytology in thyroid nodules. Cited[2011 Apr]. Available from: <http://pjmhsnline.com/>
- Muhammad Saddique, Umair-Ul-Islam, Pervez Iqbal, Qamaruddin Baloch. FNAC: a reliable diagnostic tool in solitary thyroid nodule and multinodular goiter. *Pakistan Journal of Surgery*. 2008;24(3):188-91.
- Kumar S, Aqil S, Dahar A. Role of fine needle aspiration cytology in thyroid disease. *Journal of Surgery Pakistan*. 2008 Jan-Mar;13(1):22-5.
- Hamburger JI. Diagnosis of thyroid nodules by fine needle biopsy: use and abuse. *J Clin Endocrinol Metab*. 1994 Aug;79(2):335-9.
- Godinho-Matos L, Kocjan G, Kurtz A. Contribution of fine needle aspiration cytology to diagnosis and management of thyroid Disease. *J Clin Pathol*. 1992;45(5):391-5.
- Elisei R, Bottici V, Luchetti F, Di Coscio G, Romei C, Grasso L, et al. Impact of routine measurement of serum calcitonin on the diagnosis and outcome of medullary thyroid cancer: experience in 10,864 patients with nodular thyroid disorders. *J Clin Endocrinol Metab*. 2004 Jan;89(1): 163-8.
- Are C, Hsu JF, Ghossein RA, Schoder H, Shah JP, Shah AR. Histological aggressiveness of fluorodeoxyglucose positron-emmission tomogram (FDG-PET) detected incidental thyroid carcinomas. *Ann Surg Oncol*. 2007 Nov;14(11):3210-5.