

Primary Salivary Gland Tumors in Eastern Nepal Tertiary Care Hospital

Nepal A,¹ Chettri ST,¹ Joshi RR,¹ Bhattarai M,¹ Ghimire A,¹ Karki S²

¹Department of Otolaryngology and Head Neck Surgery, Dharan, ²Department of Pathology, B. P. Koirala Institute of Health Sciences, Dharan, Nepal.

ABSTRACT

Background: The knowledge of the distribution and pattern of salivary gland tumors in the tertiary care center can provide overview of the disease pattern in the region. It also helps in planning the strategies to treat the disease and launch the awareness program in the community to this largely curable disease.

Methods: A retrospective observational study of all the salivary gland tumors treated in the department of Otolaryngology, B. P. Koirala Institute of Health Sciences during April 2004 to March 2009 was done. Age, sex, presenting features, radiological findings, histopathological type of the tumor and type of surgery were recorded and descriptive analysis was done to calculate frequencies, percentage and their relations.

Results: Out of total 51 cases, 81% (n=41) were benign and 19% (n=10) malignant tumors. Male to female ratio was 1:2.1. Mean age for benign and malignant tumors were 32.3 and 46.5 years respectively. Parotid tumor outnumbered all other sites comprising 69%, followed by submandibular 18% and minor glands 13%. Pleomorphic adenoma was the commonest tumor (76%) of all primary salivary gland tumors. Benign to malignant tumor ratio of parotid, submandibular and minor glands were 6:1, 3.5:1 and 1.3:1 respectively. Adenoid cystic carcinoma (40%) and mucoepidermoid carcinoma (30%) were commonest malignant tumors.

Conclusions: The principal site for salivary gland tumors in eastern Nepal population was the parotid and the pleomorphic adenoma outnumbered all other tumors. Most of the cases in both benign and malignant group presented with painless lump often misleading the gravity of disease.

Key words: parotid, pleomorphic, salivary, submandibular, tumor

INTRODUCTION

Salivary gland tumors are relatively uncommon and constitute 3% to 10% of all head and neck neoplasms.^{1,2} The majority (70%) of salivary gland tumors arise in the parotid gland. Although the majority of minor salivary gland tumors are malignant, three fourths of parotid tumors are benign. Environmental factors like radiation, viruses, diet, and certain occupational exposures can increase the risk of developing tumors of the salivary glands. In addition, specific genetic abnormalities

associated with the development of some types of salivary tumors have recently been well characterized.^{3,4}

Salivary gland tumors were observed in all ages but the highest incidence is observed in 3rd and 4th decade for benign tumors and 4th and 5th decades for malignant tumors.⁵

The present study was carried out with the aim to recognize various primary salivary gland tumors, their frequency and modality of their treatment in this part of the country.

Correspondence: Dr. Ajit Nepal, Department of Otolaryngology and Head and Neck Surgery, B.P. Koirala Institute of Health Sciences, Dharan, Nepal. Email: ajitnepal2001@yahoo.com, Phone: 025-525555.

METHODS

A descriptive retrospective study carried out in the department of Otolaryngology and Head Neck Surgery, B. P. Koirala Institute of Health Sciences, Dharan, Nepal from April 2004 to March 2009. Ethical approval was taken from the hospital and the patients. All 51 cases of the salivary gland tumors which were treated in the department were taken up for the study. Case details were obtained from the record section of the hospital following the ethical clearance. Details including the sex, age, presenting features, extent of tumor, radiological findings, histopathological type of the tumor and type of surgery were recorded. Ultrasonography was done in all benign tumors of major salivary gland tumors while computer tomography was done in all cases of malignant tumors and selected benign tumors of major salivary glands. Various cysts, sialadenitis and tumors arising from tissues other than proper salivary gland were excluded from the study. The data were analyzed using Microsoft Excel 2003.

RESULTS

Total of 51 cases were observed during the course of 5 years study out of which 81% (n=41) were benign and 19% (n=10) malignant tumors. Age distribution ranged

from 15 to 73 years of age with mean age 39.4 years for all the tumors. However the mean age for benign and malignant tumors was 32.3 and 46.5 years respectively. The highest incidence was in the 3rd to 4th decade for benign and 5th to 6th decade for malignant tumors (Table 1). All benign tumors except two were pleomorphic adenomas. Both the cases of Warthin's tumor were of 7th decade, one from each sex. Overall male to female ratio was 1:2.1. Parotid tumor outnumbered all other sites comprising 69%, while 18% were submandibular and the minor glands were found to be 13%. Over half of the minor gland tumor had their origin in palate. No any sublingual tumor was found during the period (Table-2). Pleomorphic adenoma was the commonest tumor (76%) of all primary salivary gland tumors and parotid was the commonest site (55%). Out of 41 benign tumors parotid constituted 73%(n=30), submandibular 17%(n=7) and the minor glands 10%(n=4). Malignant tumors were also found more in parotid glands constituting 50% (n=5) of all malignant salivary gland tumors while minor glands and submandibular gland comprised 30%(n=3) and 20%(n=2) in the group respectively. Benign to malignant tumor ratio of parotid, submandibular and minor glands were 6:1, 3.5:1 and 1.3:1 respectively (Chart-1). Adenoidcystic carcinoma was the most common malignant primary salivary gland tumor (40%) followed by mucoepidermoid carcinoma (30%).

Table 1. Age and Sex distribution of benign and malignant salivary gland tumors

Age	Male		Female		Frequency (%)
	Benign	Malignant	Benign	Malignant	
≤20 years	1	-	4	-	5(10)
21-40 years	7	1	14	2	24(47)
41-60 years	5	1	8	3	17(33)
> 60 years	-	1	3	1	5(10)
Frequency (%)	13(25)	3(6)	29(57)	6(12)	51(100)

Table 2. Site distribution of the salivary gland tumors

Tumor	Parotid	Submandi- bular	Palate	Upper lip	Nasal cavity	Cheek	Frequency (%)
Benign							
Pleomorphic Adenoma	28	7	3	-	-	1	39(76)
Warthin's Tumor	2	-	-	-	-	-	2(4)
Malignant							
Adenoid Cystic Carcinoma	2	-	1	-	1	-	4(8)
Mucoepidermoid Carcinoma	2	-	-	1	-	-	3(6)
Carcinoma Ex-Pleomorphic Adenoma	1	1	-	-	-	-	2(4)
Squamous Cell Carcinoma	-	1	-	-	-	-	1(2%)
Frequency (%)	35(69)	9(17)	4(8)	1(2)	1(2)	1(2)	51(100)

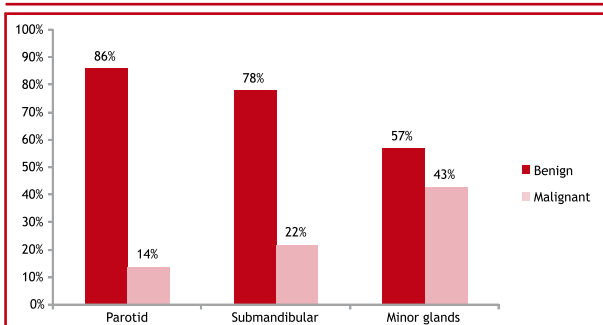


Figure 1. Incidence of the benign and malignant neoplasm according to the site of origin.

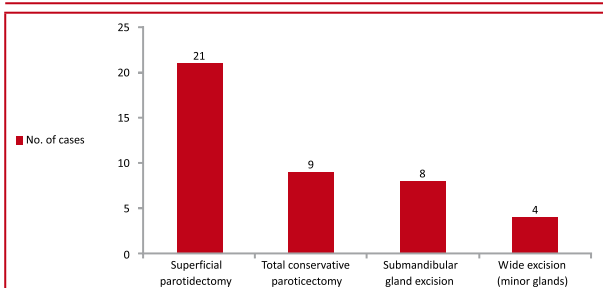


Figure 2. Treatment modality of benign tumors

All patients of major salivary gland presented with a swelling or palpable mass. Local pain was present in 11 cases (21.5%) of which six were malignant and five benign. Both cases of Warthin’s tumor had history of recurrent pain and swelling. Two cases of malignant tumors had facial nerve paralysis at presentation one each in adenoid cystic and mucoepidermoid carcinoma. Cervical lymph node metastasis was found in four cases, two in adenoid cystic carcinoma and one each in mucoepidermoid and squamous cell carcinoma. Moreover one case of adenoid cystic carcinoma of floor of nasal cavity had atypical presentation of recurrent epistaxis.

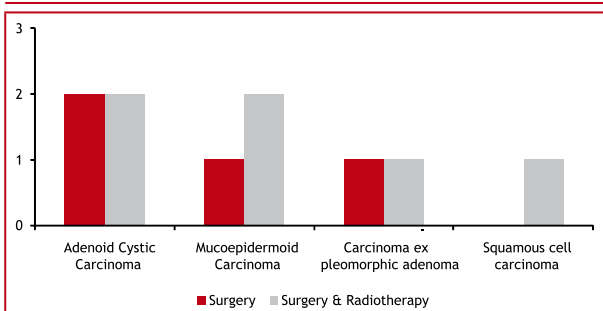


Figure 3. Treatment modality for malignant tumors (in numbers).

All parotid, submandibular, three palatal and one upper lip tumors (n=48) cases were subjected to FNAC and postoperative histopathological examinations. Overall, total 46 FNAC diagnosis correlated histopathological examinations with 95.8% accuracy. One case of palatal

and buccal each direct excision biopsy was done which turned out to be pleomorphic adenoma. Punch biopsy was taken in the case of that presented with recurrent epistaxis which had friable mass in the floor left nasal cavity establishing the diagnosis of the adenoid cystic carcinoma.

There were total four (7.8%) recurrent salivary gland tumors, three cases in parotid and one submandibular. All three cases of parotid had undergone superficial parotidectomy for pleomorphic adenoma, two in our own institution and one other centre some 5-7 years back. One submandibular gland surgery was done in other center previously and no any documentation was available. Carcinoma ex-pleomorphic adenoma one each from parotid and submandibular glands was from these recurrent groups.

Various modalities of treatment carried out for both the benign and malignant groups are shown in the chart 2 and 3 respectively.

DISCUSSION

Present study of 51 cases of major and minor salivary gland tumors revealed predominance of benign (81%), compared to malignant tumors (19%) which were similar to a series 124 cases by Vagas et al in a Brazilian population.⁶ Studies by Ahmad et al in Kashmir and Satko et al in Slovakian population were also comparable to our study.^{5,7} They also showed the highest incidence of benign tumors in 3rd to 4th decade and malignant tumors in 4th to 5th decade of life in consistent with our study. Mean age for benign and malignant tumors was 32.3 years and 46.5 years respectively in our cases. Ahmed et al found mean age 35.7 for benign tumors and 42.4 for malignant ones.

Our study showed almost 2/3rd of the patients to be females. Vegas et al found female to male ratio to be 1.5: 1 as well in their series. Most of the world literature shows the female predominance in salivary gland tumors.^{8,9} In contrast, Frade et al found a male predominance (58.75%) in their study.¹⁰

Parotid tumor outnumbered all other sites comprising 69%, while 18% were submandibular and the minor glands were found to be 13%. Pleomorphic adenoma was the commonest tumor (76%) of all primary salivary gland tumors and parotid was the commonest site (55%). Other studies of salivary gland tumors also showed the single predominance of pleomorphic adenoma ranging from 50% to 80% followed by submandibular and minor salivary glands.^{3,7,10}

No any sublingual tumor was found in our series. Vagas et al also didn’t find any tumor of sublingual origin in

their series of 214 cases while Eveson et al observed one sublingual tumor to 100 parotid tumors in their series of 2410 cases.^{1,6} In contrast, Satko et al reported unusually high incidence of 33 cases of sublingual tumors in their series of 1021 cases.⁷

We found only 5% (n=2) of the benign tumors to be Warthin's tumor, both were unilateral parotid and 6th decade one from each sex. The peak incidence of Warthin's tumor is 6th decade and it is predominant in males.⁹ Vegas et al found only one bilateral case out of 13 cases of Warthin's tumors in his series.⁶

Adenoid cystic carcinomas were the commonest malignant tumor found in our series comprising 8% (n=4) of the total tumors followed by mucoepidermoid carcinoma 6% (n=3). These two are the commonest malignant salivary gland tumors cited in the world literatures.^{11,12} We found two cases each in parotids and minor glands. Pinkston et al in their series noted mucoepidermoid carcinomas to be more common in parotids.¹² In our study, two were in parotids in 2 cases while one in upper lip. In review of 242 patients with adenoid cystic carcinoma, Spiro et al found that over 2/3rd of the cases occurred in minor salivary glands.¹³ We found two cases each in parotids and minor glands.

Primary squamous cell carcinoma of salivary gland is rare. Batsakis et al indicated that the true incidence to be 0.3% to 1.5%.¹⁴ We found only one case of squamous cell carcinoma in submandibular gland in our series.

Since the study design was retrospective with a small sample size and hospital based, it has its own limitation, hence a multicentric approach with higher level of association is recommended.

CONCLUSIONS

The principal site for salivary gland tumors in eastern Nepal population was the parotid and the pleomorphic adenoma outnumbered all other tumors. Most of the cases in both benign and malignant group presented with painless lump often misleading the gravity of disease. Timely diagnosis and surgical intervention remains the mainstay of management. Community awareness programme is recommended to achieve this goal.

REFERENCES

1. Eveson JW, Cawson RA. Salivary gland tumours. A review of 2410 cases with particular reference to histological types, site, age and sex distribution. *J Pathol.* 1985 May;146(1):51-8.
2. Arotiba GT. Salivary gland neoplasms in Lagos, Nigeria. *West Afr J Med.* 1996 Jan-Mar;15(1):11-7.
3. Spiro RH. Salivary neoplasms: Overview of a 35-year old experience with 2,805 patients. *Head Neck Surg* 1986;8(3):177-84.
4. Hanna EY, Lee S, Fan CY, Suen JY. Benign neoplasm of the salivary glands In: *Otolaryngology- Head & Neck Surgery: Charles W Cummings ed. 4th ed. Philadelphia: Elsevier Mosby; 2005. p.349-51.*
5. Ahrnad S, Lateef M, Ahmad R. Clinicopathological study of primary salivary gland tumors in Kashmir. *JK-Practitioner.* 2002; 9(4):231-3.
6. Vargas PA, Gerhard R, Araújo Filho VJ, de Castro IV. alivary gland tumors in a Brazilian population: a retrospective study of 124 cases. *Rev Hosp Clin Fac Med Sao Paulo.* 2002 Nov-Dec;57(6):271-6.
7. Satko I, Stanko P, Longauerová I. Salivary gland tumours treated in the stomatological clinics in Bratislava. *J Craniomaxillofac Surg.* 2000 Feb;28(1):56-61.
8. Gleeson M, Cawson R. Benign salivary gland tumors In: *Scott-Brown's Otolaryngology Head and Neck Surgery: Michael Gleeson ed. 7th ed. London: Hodder Arnold; 2008. p.2475.*
9. Batsakis JG, Regezi JA. The pathology of head and neck tumors: Salivary glands, part1. *Head Neck Surg.* 1978;1:59-68.
10. Frade Gonzalez C, Lozano Ramirez A, Garcia Caballero T, Labella Caballero T. Epidemiological study of salivary gland tumours. *Rev Laryngol Otol Rhinol (Bord).* 1999;120(5):331-6.
11. Spitz MR, Batsakis JG. Major Salivary Gland Carcinoma Descriptive Epidemiology and Survival of 498 Patients. *Arch Otolaryngol.* 1984;110(1):45-9.
12. Pinkston JA, Cole P. Incidence rates of salivary gland tumors: Results from a population based study. *Otolaryngol head Neck Surg.* 1999;120:834-40.
13. Spiro RH, Huvos AG, Strong EW. Adenoid cystic carcinoma of salivary origin: A clinicopathologic study of 242 cases. *Am J Surg.* 1974;128:512-20.
14. Batsakis JG, McClatchey KD, Johns M. Primary squamous cell carcinoma of the parotid gland. *Arch Otolaryngol.* 1976;102:355-57.